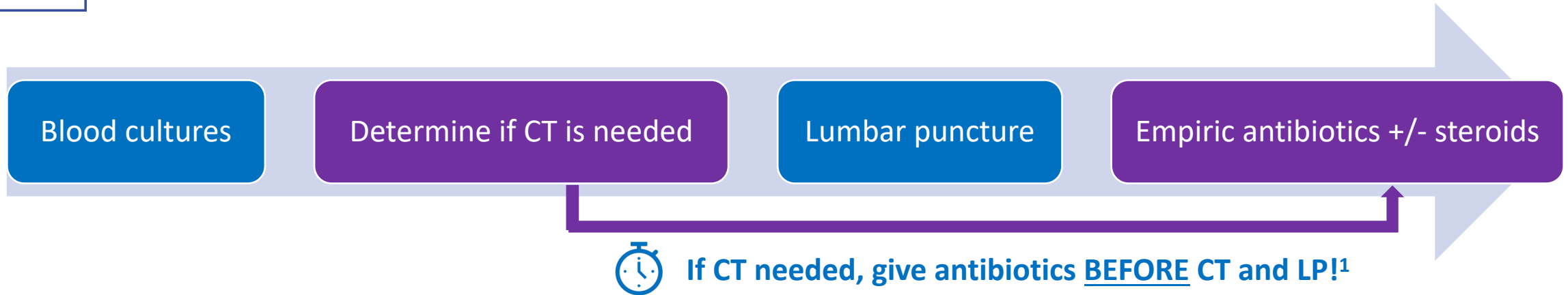


Imaging Before Lumbar Puncture



IDSA Indications for Imaging Before LP*²

Immunocompromised state

History of CNS disease

New onset seizure within 1 week

Papilledema

Abnormal level of consciousness

Focal neurologic deficit



¹Glimåker M, Sjölin J, Åkesson S, Naucner P. Lumbar Puncture Performed Promptly or After Neuroimaging in Acute Bacterial Meningitis in Adults: A Prospective National Cohort Study Evaluating Different Guidelines. Clin Infect Dis. 2018 Jan 18;66(3):321-328. doi: 10.1093/cid/cix806. PMID: 29020334.

²Tunkel AR, Hartman BJ, Kaplan SL, et al. Practice guidelines for the management of bacterial meningitis. Clin Infect Dis 2004; 39:1267-84.